



Available online at
ScienceDirect
www.sciencedirect.com

Elsevier Masson France
EM|consulte
www.em-consulte.com/en



Original article

Polyurethane scaffold in lateral meniscus segmental defects: Clinical outcomes at 24 months follow-up

H. Bouyarmane^{a,b}, P. Beaufils^{a,*}, N. Pujol^a, J. Bellemans^c, S. Roberts^d, T. Spalding^e, S. Zaffagnini^f, M. Marcacci^f, P. Verdonk^g, M. Womack^h, R. Verdonkⁱ

^a Service d'Orthopédie Traumatologie, Centre Hospitalier de Versailles, Université Versailles-Saint Quentin, rue de Versailles, 78150 Le Chesnay, France

^b Orthopaedic Surgery Center, 71, boulevard d'Anfa, Casablanca 20060, Morocco

^c Catholic University Hospitals, Langdorp, Belgium

^d Orthopaedic Hospital, Oswestry, United Kingdom

^e University Hospitals, Coventry, United Kingdom

^f Istituto Ortopedico Rizzoli, Bologna, Italy

^g Antwerpen Orthopaedic center, Antwerp, Belgium

^h Orteq Sports Medicine, London, United Kingdom

ⁱ Ghent University Hospital, Ghent, Belgium

ARTICLE INFO

Article history:

Accepted 18 October 2013

Keywords:

Lateral meniscus
Meniscectomy
Scaffold
Arthroscopy
Knee

ABSTRACT

Background: Segmental tissue loss in the lateral meniscus is associated with pain and increased risk of osteoarthritis even when indications have been carefully considered.

Hypothesis: Repairing the defect using a novel biodegradable scaffold will reduce pain and restore the knee function.

Methods: In this prospective multicenter study, a total of 54 patients (37 males/17 females; mean age: 28 years [16–50]) were enrolled. All patients presented with postmeniscectomy syndrome and segmental lateral meniscus loss, and were treated with a polyurethane biodegradable scaffold (Actifit[®], Orteq) implanted arthroscopically. Clinical outcomes were assessed at 6, 12 and 24 months using Visual Analogue Scale (VAS), International Knee Documentation Committee Score (IKDC) and Knee Injury and Osteoarthritis Outcome Score (KOOS).

Results: VAS decreased from 5.5 at baseline to 3.6 at 6 months, 3.4 at 12 months and 2.9 at 24 months. IKDC improved from 47.0 at baseline to 60.2, 67.0 and 67.0 at 6, 12 and 24 months. All KOOS subscores improved between baseline and 24 months.

Discussion: Clinical results of this study demonstrate clinically and statistically significant improvements of pain and function scores (VAS, IKDC, and all KOOS subscales except sport), at the 6 months follow-up and on all clinical outcomes at the 2-year follow-up. The Actifit[®] scaffold is safe and effective in treating lateral meniscus defects.

Level of evidence: IV: continuous prospective multicenter study.

© 2013 Elsevier Masson SAS. All rights reserved.

1. Introduction

The menisci play an important biomechanical role in the knee including load bearing, load and force distribution between the femoral condyles and tibial plateau, joint stabilization, lubrication and proprioception [1]. This is especially important in the lateral compartment which is considered to be more biomechanically challenging, as the lateral meniscus has a smaller contact area combined with higher peak stresses when compared to the medial meniscus under various loads, degrees of flexion and meniscectomy

conditions. Furthermore, the lateral compartment is more mobile than the medial as the antero-posterior translation is greater [2,3].

The standard of care for irreparable meniscal tears, partial lateral meniscectomy, is well known to predispose patients to long-term degenerative changes and osteoarthritis [4,5]. Furthermore, worse outcomes have been reported following lateral rather than medial meniscectomy [6,7]. In a 30-year longitudinal study, McNicholas et al. [8] found that after medial meniscectomy 80% of patients had good or excellent results at long-term follow-up, compared to only 47% after lateral meniscectomy, thus there are even greater negative consequences following meniscal tissue loss in the lateral compartment. Chatain [6] when comparing results of 109 lateral and 362 medial partial meniscectomies with more than 10 years follow-up concludes that subjective and clinical results are quite

* Corresponding author. Tel.: +33 01 39 63 89 51.

E-mail address: pbeaufils@ch-versailles.fr (P. Beaufils).

similar but radiographic results, in particular, joint space narrowing are significantly worse in the lateral compartment.

The unacceptably low rate of success following lateral partial meniscectomy, common to all current standard procedures, has led to a genuine need for an approach which will offer patients better and more reliable treatment. Meniscal reconstruction would be the solution to this problem; by allograft in the case of total meniscectomy or scaffold in the case of a partial defect with the aim of closely mimicking the shape and biomechanical properties of the native meniscus [9,10]. The novel porous biodegradable polyurethane scaffold (Actifit®) is intended to meet this unmet need, by providing a scaffold for vessel ingrowth and meniscal tissue regeneration. Studies have shown that treatment of irreparable meniscal tissue loss with the polyurethane scaffold is both safe and efficacious in mixed populations of medial and lateral patients [11,12]. However, no data are currently available that focus on the more biomechanically challenging lateral indication.

The objective of this study was to clinically evaluate the lateral polyurethane scaffold for the treatment of patients with lateral segmental tissue loss with postmeniscectomy syndrome. We hypothesize that the lateral polyurethane meniscal scaffold, indicated in case of partial defect, is able to reduce pain and restore knee function.

2. Materials and methods

This study was a prospective, single-arm, multicentre study designed to assess the safety and efficacy of the lateral polyurethane meniscal scaffold (Actifit®, Orteq Ltd, London, UK) for the treatment of postmeniscectomy syndrome (Fig. 1a). A total of

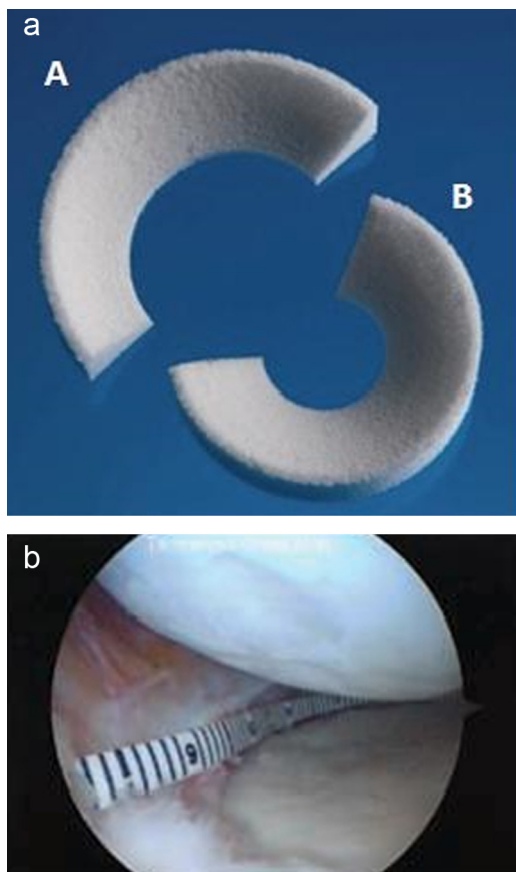


Fig. 1. a: the polyurethane scaffold is available in both medial (A) and lateral (B) configurations; b: measurement of defect length.

54 patients from six European centres were enrolled between 2007 and 2011 who were treated with the polyurethane scaffold for postmeniscectomy syndrome. Inclusion criteria were the same as used by Verdonk et al. [11], but in brief comprised; (1) irreparable painful lateral meniscal tear or partial meniscus loss, with intact rim; (2) skeletally mature male or female patients; (3) age 16 to 50 years; (4) stable knee joint or knee joint stabilization procedure within 12 weeks of index procedure; (5) International Cartilage Repair Society (ICRS) classification ≤ 3 and (6) body mass index ≤ 35 .

2.1. Surgical technique

Following exploration of all compartments and verification of cartilage status, debridement and preparation were performed: the defects extended into the vascularized red-on-red or red-on-white zone of the damaged portion of the meniscus. The meniscal defect was measured along the curvature of its inner edge using a special meniscal ruler (Fig. 1b), then the scaffold was cut to size; with the scaffold oversized by 10% to allow for shortening caused by suturing. The implant was introduced into the joint by the anterolateral portal and then fixed to the native meniscus by sutures (using all inside devices, and/or outside-in techniques) (Fig. 2).

2.2. Rehabilitation

Following the implantation of Actifit® scaffold, rehabilitation was provided as per the procedure described by Verdonk et al. [13].

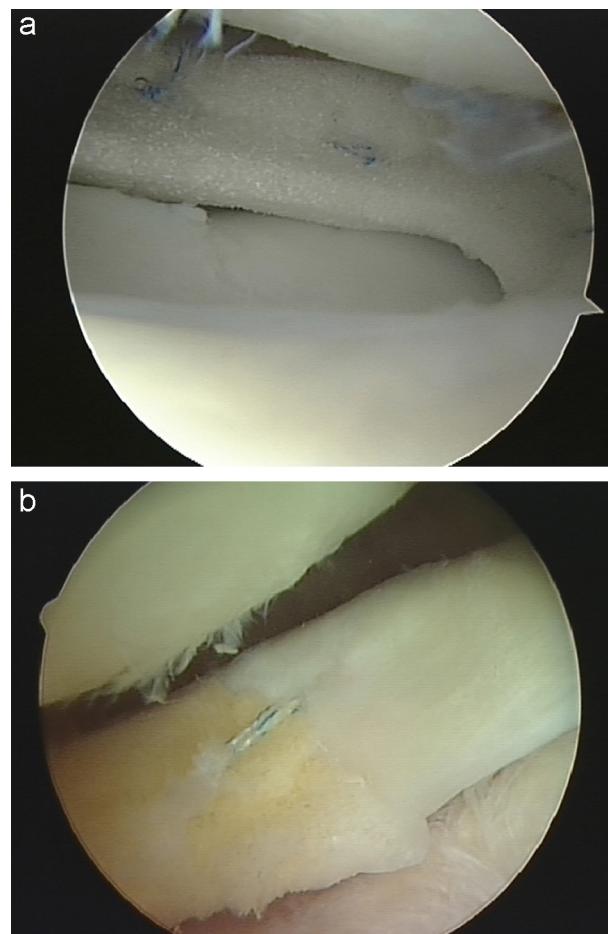


Fig. 2. a: suture of scaffold to native meniscus; b: 24-month relook showing tissue ingrowth into the scaffold at the interface with the native meniscus. Courtesy S. Roberts.

Rehabilitation took place over 16–24 weeks, with the patient non-weight-bearing for the first 3 weeks, partial weight-bearing from week 4 with gradual increase in loading up to 100% load at 9 weeks post-implantation. Flexion was progressively increased from 30° during 2 weeks to 60° in week 3 and 90° in weeks 4 and 5. From week 6 onwards, flexion is further increased until a full range of motion is achieved. Light exercise, including isometric quadriceps exercises, mobilisation of the patella, heel slides, quad sets, anti-equinus foot exercises and Achilles tendon stretching, is advised from week 1.

2.3. Clinical outcomes

Patients were assessed at 6, 12 and 24 months postoperatively follow-up visits using the VAS, IKDC scores and KOOS clinical outcome scores.

2.4. Statistical methods

All evaluations were based on all patients enrolled into the study and implanted with the scaffold. The last observation carried forward (LOCF) [14,15] approach was used; that is data from the last available follow-up visit were used in place of missing scores due to patient withdrawal, loss to follow-up, or non-evaluable VAS or other outcome questionnaire data. Total clinical outcome scores were calculated according to standard formulae. Absolute and change from pre-surgery values were analyzed descriptively (including mean and 95 CI). And paired *t*-tests to test the null hypothesis of mean change in outcome scores equal to zero were carried out for each outcome score at each follow-up assessment (a 2-sided $P < 0.05$ was considered statistically significant).

3. Results

There were 37 men and 17 women (mean age: 28 years, range 16–50 years) enrolled in the study. All patients presented with postmeniscectomy syndrome following 1–3 prior meniscal surgeries. There were 9 patients who had undergone anterior cruciate ligament reconstruction and 5 patients who had undergone distal femoral varus osteotomies prior to taking part in this study.

The mean size of defect was 43 mm (32–60 mm). The lateral defects were primarily localized in both posterior and middle segments of the meniscus in 45% of cases, posterior in 27%, midpart in 23% and across the segments for 5% of cases. At the time of Actifit® implantation, four patients received distal femoral varus osteotomy, one underwent chondral-shaving, one had a mobile loose body removed and one underwent a microfracture procedure.

3.1. Clinical outcome scores

There were no intra- or immediate postoperative complications. By 6 months, all clinical outcome scores showed clinically significant improvements from baseline, a trend which continued on to 12 months. Between 12 and 24 months, VAS continued to improve (Fig. 3), IKDC and KOOS Quality of Life showed no significant regression, and the pain, symptoms, activities of daily living and sports domains of KOOS continued to improve (Figs. 4 and 5). Overall there were clinically and statistically significant improvements from baseline to 24 months for all clinical outcome scores (Table 1).

3.2. Reoperations

During the course of 24 months follow-up period, a total of 3/54 (5.5%) patients underwent exploratory arthroscopy due to pain. One of these patients, prior to receiving the scaffold, had medial

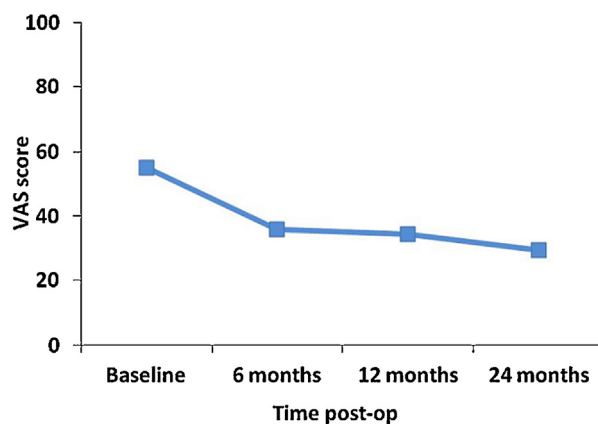


Fig. 3. VAS improvement from baseline (last observation carried forward) to 24 months.

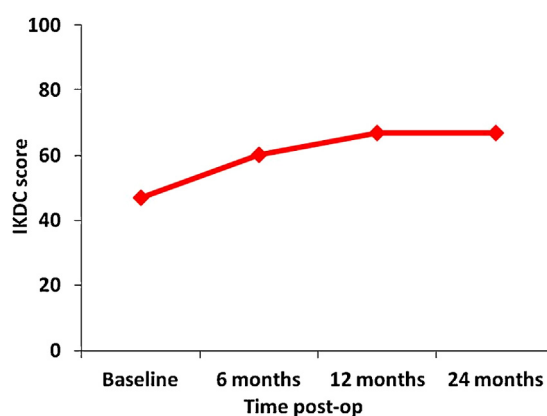


Fig. 4. IKDC improvement from baseline (last observation carried forward) to 24 months.

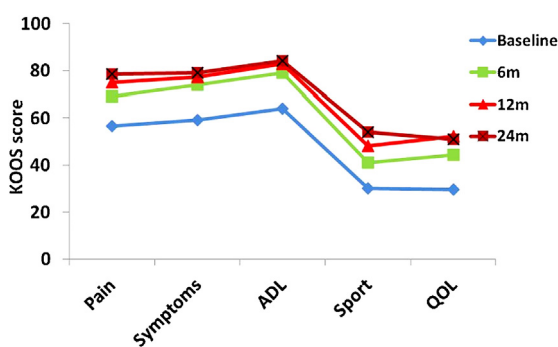


Fig. 5. KOOS subscales improvement from baseline (last observation carried forward) to 24 months.

femoral condyle osteochondritis dissecans and had undergone ACL reconstruction. After 7 months, a part of scaffold was removed, outcomes were good at 3 years follow-up. The second patient, re-operated 15 months post-implantation for pain, had small tear localised in free edge of the scaffold which was trimmed to prevent propagation. However, even though the scaffold was well integrated, pain continued. In the third case, the patient was re-operated on for new pain at 24 months postoperatively. A torn part of the scaffold was removed.

Results of these re-operated patients are included in the statistics of our study.

Table 1
Clinical outcome scores, VAS, IKDC and KOOS from baseline to 24 months.

Score	Baseline	6 months	12 months	24 months	(LOCF) n
VAS	5.51 ± 2.32	3.58 ± 2.63*	3.4 ± 2.70*	2.94 ± 2.52*	45
IKDC	46.96 ± 15.67	60.19 ± 20.20**	67.04 ± 20.24*	66.97 ± 18.34*	42
KOOS Symptoms	59.16 ± 19.42	73.84 ± 14.90*	77.33 ± 16.28	79.01 ± 16.11	30
KOOS Pain	56.57 ± 17.61	69.15 ± 18.72***	75.03 ± 18.45*	78.53 ± 17.24*	30
KOOS ADL	64.06 ± 23.05	79.02 ± 16.33**	82.96 ± 16.96*	84.21 ± 15.26*	30
KOOS Sport	30.05 ± 26.87	41.16 ± 27.42 (NS)	48.10 ± 28.82****	54.03 ± 27.25****	27
KOOS QOL	29.59 ± 16.94	44.42 ± 22.21**	52.18 ± 21.38*	50.93 ± 21.38*	30

Mean ± standard deviation. NS: not significant.

* $P < 0.0001$.

** $P < 0.0005$.

*** $P < 0.005$.

**** $P < 0.05$.

4. Discussion

The first generation of meniscal scaffolds (collagen meniscal implant [CMI]) used to treat meniscal defects have been shown to provide significant improvements in function using the Lysholm and Tegner index [16–18]. Zaffagnini et al. [10] in a 10-year minimum follow-up study found statistically significant improvements in both clinical and radiological outcomes in the CMI group when compared with partial meniscectomy. Clinical evaluation using pain, Lysholm scores and the Tegner index demonstrated significant improvements at 5-year follow-up which was maintained up to the 10 years follow-up. The CMI is made from type 1 collagen derived from bovine achilles tendon, and has been reported to present difficulty in handling and suturing during surgery, highlighting the need for newer scaffolds with improved material and handling characteristics.

The second generation porous polyurethane scaffold is robust and flexible when handling and has been reported to degrade into non-toxic decomposition products [19,20], as well as supporting migration of cells and ingrowth of new tissue *in vitro* and *in vivo* [11,21]. Preservation of cartilage status following implantation of the polyurethane scaffold has also been demonstrated in several studies [13,22]. In addition, the frictional properties of the porous polyurethane scaffold have been shown to approach those of native meniscus after 6 to 12 months in sheep [23].

This is the first study to focus solely on the use of the polyurethane meniscal scaffold in the more challenging lateral indication. The main finding from this study is that lateral Actifit® meniscal scaffold is both safe and effective when used to treat patients presenting with postmeniscectomy syndrome. Clinical results presented here demonstrate clinically and statistically significant improvements of pain and function scores (VAS, IKDC, and all KOOS subscales except sport) already at the 6 months follow-up and on all clinical outcome scores between baseline and the 2-year follow-up. With the exception of the VAS pain scores which continue a trend of improvement between baseline through to 2 years, the majority of improvement of the other clinical outcome scores were achieved during the first year. Progression of these scores between 12 and 24 months is not significant. Our results are in agreement with those published by Verdonk et al. [12] who reported comparable clinically and statistically significant improvements of all clinical outcome scores, in a 52-patient study (34 medial and 18 lateral). Efe et al. [22] in a study consisting of 10 patients with pain as a result of segmental medial meniscus loss, treated with Actifit®, also found clinically and statistically significant improvement of KOOS scores from baseline to 12 months. The improvement in VAS pain scale reported by Efe did not reach statistical significance however, but patients were reported as being satisfied with the results of their surgery and when asked if they would have the procedure repeated, all said yes.

Radial displacement of polyurethane scaffold has been studied by De Coninck et al. [24]. The radial displacement of lateral scaffold was not significant between implantation and 24 months follow-up relative to preoperative status, however this displacement increased significantly for medial scaffold.

The reoperation rate of 5.5% (3/54) reported here using the polyurethane scaffold compares favourably with other forms of meniscal surgery such as repair surgery previously reported: bio-absorbable meniscal screws and arrows (33–68% reoperations reported [25–28]) and all inside suture techniques (13–29% reoperations reported [29–32]). However, it must be noted that a direct comparison with such techniques is not possible, as they would not be indicated for the more challenging population of patients reported in this study that had irreparable defects with limited treatment options.

4.1. Limitations

A limitation of this single-arm study is the lack of a control group of patients undergoing partial meniscectomy allowing a direct comparison of the two treatment options. There are currently no randomised control studies which assess the Actifit® scaffold; however, previous meniscal scaffold (CMI Menaflex™ Regen Biologics) studies [10,16,17] have demonstrated benefits with scaffolds both in terms of clinical results and cartilage preservation, when compared with partial meniscectomy. Another limitation of the multicentre approach utilised in this study was that potential bias and variation that could have been introduced from data capture at each centre. The data was reviewed and collated by an independent assessor in order to mitigate any potential bias.

5. Conclusion

The frequency of sequelae following lateral meniscectomy demonstrates the need for an effective treatment option. This clinical study demonstrates both the safety and efficacy of the polyurethane scaffold used to treat partial defects of the lateral meniscus at 24 months following implantation, thus providing surgeons with such a treatment option in this challenging patient population. Further long-term research is required to further support the findings from this mid-term study.

Disclosure of interest

H. Bouyarmane, N. Pujol, J. Bellemans, S. Roberts, S. Zaffagnini, M. Marcacci: declare that they have no conflicts of interest concerning this article.

P. Beaufils: educational consultant for Orteq and Smith and Nephew.

P. Verdonk: educational consultant for Orteq and Smith and Nephew.

R. Verdonk: educational consultant for Orteq.

T. Spalding: educational consultant for Orteq and Smith and Nephew.

M. Womack: employee of Orteq Sports Medicine.

References

- [1] Fetzer GB, Spindler KP, Amendola A, Andrish JT, Bergfeld JA, Dunn WR, et al. Potential market for new meniscus repair strategies: evaluation of the MOON cohort. *J Knee Surg* 2009;22:180–6.
- [2] Mc Dermott ID, Amis AA. The consequences of meniscectomy. *J Bone Joint Surg Br* 2006;88:1549–56.
- [3] Beaufils P, Hardy P, Chambat P, Clavert P, Djian P, Frank A, et al. Adult lateral meniscus. *Rev Chir Orthop* 2006;92, 2S169–94.
- [4] Fairbanks TJ. Knee joint changes after meniscectomy. *J Bone Joint Surg Br* 1948;30:664–70.
- [5] Chambat P, Sonneroy-Cottet B, Guier C. Management of early and late failure of lateral meniscus. In: Beaufils P, Verdonk R, editors. *The meniscus*. Springer-Verlag Heidelberg; 2010. p. 289–96.
- [6] Chatain F, Adeleine P, Chambat P, Neyret PA. comparative study of medial versus lateral arthroscopic partial meniscectomy on stable knee: a 10 years minimum follow-up. *Arthroscopy* 2003;19(8):842–9.
- [7] Simpson DA, Thomas NP, Aichroth PM. Open and closed meniscectomy: a comparative analysis. *J Bone Joint Surg Br* 1986;68B:301–4.
- [8] McNicholas MJ, Rowley DI, McGurty D, et al. Total meniscectomy in adolescence: a thirty-year follow-up. *J Bone Joint Surg Br* 2000;82B:217–21.
- [9] Rodkey WG, DeHaven KE, Montgomery III WH, Baker Jr CL, Beck Jr CL, Hormel SE, et al. Comparison of the collagen meniscus implant with partial meniscectomy: a prospective randomized trial. *J Bone Joint Surg Am* 2008;90:1413–27.
- [10] Zaffagnini S, Muccioli GMM, Lopomo N, Bruni N, Giordano G, Ravazzolo G, et al. Prospective long-term outcomes of the medial collagen meniscus implant versus partial medial meniscectomy. *Am J Sports Med* 2011;39(5):977–85.
- [11] Verdonk R, Verdonk P, Huysse W, et Forsyth R, Heinrichs EL. Tissue ingrowth after implantation of a novel biodegradable polyurethane scaffold for treatment of partial meniscal lesions. *Am J Sports Med* 2011;39:774–82.
- [12] Verdonk P, Beaufils P, Bellemans J, Djian P, Heinrichs EL, Huysse W, et al. Successful treatment of painful irreparable partial meniscal defects with a polyurethane scaffold; two-year safety and clinical outcomes. *Am J Sports Med* 2012;40:844–53.
- [13] Verkonk R, Verdonk P, Heinrichs EL. Polyurethane meniscus implant. In: *The meniscus*. Springer-Verlag Heidelberg; 2010. p. 389–94.
- [14] Herman A, Botser IB, Tenenbaum S, Chechick A. Intention-to-treat analysis and accounting for missing data in orthopaedic randomized clinical trials. *J Bone Joint Surg Am* 2009;91:2137–43.
- [15] Points to consider on missing data from the Committee for Proprietary Medicinal Products of the European Medicines Agency (EMA). <http://www.emea.europa.eu/pdfs/human/ewp/177699EN.pdf> (accessed 31 January 2011).
- [16] Bulgheroni P, Murena L, Ratti C, Bulgheroni E, Ronga M, Cherubino P. Follow-up of collagen meniscus implant patients: clinical, radiological, and magnetic resonance imaging results at 5 years. *Knee* 2010;17:224–9.
- [17] Steadman JR, Rodkey WG. Tissue-engineered collagen meniscus implant: 5 to 6 years feasibility study results. *Arthroscopy* 2005;21:515–25.
- [18] Zaffagnini S, Maria G, Muccioli M, Grassi A, Bonanzinga T, Filardo G, et al. Arthroscopic lateral collagen meniscus implant in a professional soccer player. *Knee Surg Sports Traumatol Arthrosc* 2011;19:1740–3.
- [19] Tienen TG, Heijkants RGJC, Burma P, De Groot JH, Pennings AJ, Veth RPH. A porous polymer scaffold for meniscal lesion repair – A study in dogs. *Biomaterials* 2003;24:2541–8.
- [20] Pereira H, Frias AM, Oliveira JM, Espregueira-Mendes J, Reis RL. Tissue engineering and regenerative medicine strategies in meniscus lesions. *Arthroscopy* 2007;27(12):1706–19.
- [21] Maher SA, Rodeo SA, Doty SB, Brophy R, Potter H, Foo LF. Evaluation of a porous polyurethane scaffold in a partial meniscal defect ovine model. *Arthroscopy* 2010;26(11):1510–9.
- [22] Efe T, Getgood A, Schofer MD, Fuchs-Winkelmann S, Mann D, Paletta JR, et al. The safety and short-term efficacy of a novel polyurethane meniscal scaffold for the treatment of segmental meniscus deficiency. *Knee Surg Sports Traumatol Arthrosc* 2012;20:1822–30.
- [23] Galley NK, Gleghorn JP, Rodeo S, Warren RF, Maher SA, Bonassar LJ. Frictional properties of the meniscus improve after scaffold-augmented repair of partial meniscectomy: a pilot study. *Clin Orthop Relat Res* 2011;469:2817–23.
- [24] De Coninck T, Huysse W, Willemot L, Verdonk R, Verstraete K, Verdonk P. Two-year follow-up study on clinical and radiological outcomes of polyurethane scaffolds. *Am J Sports Med* 2013;41:64–72.
- [25] Järvelä S, Sihvonen R, Sirkeoja H, Järvelä T. All-inside meniscal repair with bioabsorbable meniscal screws or with bioabsorbable meniscus arrows: a prospective, randomized clinical study with 2-year results. *Am J Sports Med* 2010;38:2211–7.
- [26] Gifstad T, Grøntvedt T, Drogset JO. Meniscal repair with biofix arrows: results after 4.7 years' follow-up. *Am J Sports Med* 2007;35:71–4.
- [27] Cardello P, Gigli C, Ricci A, Chiatti L, Vogliano N, Pofi E. Retears of postoperative knee meniscus: findings on magnetic resonance imaging (MRI) and magnetic resonance arthrography (MRA) by using low and high field magnets. *Skeletal Radiol* 2009;38:149–56.
- [28] Gallacher PD, Gilbert RE, Kanes G, Roberts SN, Rees D. White on white meniscal tears to fix or not to fix? *Knee* 2010;17:270–3.
- [29] Pujol N, Tardy N, Boisrenoult P, Beaufils P. Long-term outcomes of all-inside meniscal repair. *Knee Surg Sports Traumatol Arthrosc* 2013 [Epub ahead of print].
- [30] DeHaan A, Rubinstein Jr RA, Baldwin JL. Evaluation of success of a meniscus repair device for vertical unstable medial meniscus tears in ACL-reconstructed knees. *Orthopedics* 2009;32 [pii: orthosupersite.com/view.asp?rID=38346].
- [31] Logan M, Watts M, Owen J, Myers P. Meniscal repair in the elite athlete: results of 45 repairs with a minimum 5-year follow-up. *Am J Sports Med* 2009;37:1131–4.
- [32] Barber FA, Schroeder FA, Oro FB, Beavis RC. FasT-Fix meniscal repair: mid-term results. *Arthroscopy* 2008;24:1342–8.